
Artisan aphakic intraocular lens in children with subluxated crystalline lenses

Tova Lifshitz, MD, Jaime Levy, MD, Itamar Klemperer, MD

Purpose: To evaluate the results of Artisan® (Ophtec) aphakic intraocular lens (IOL) implantation in children with idiopathic subluxated lenses.

Setting: Department of Ophthalmology, Soroka University Medical Center, Beer-Sheva, Israel.

Methods: This retrospective small case series comprised 4 eyes (3 children) with idiopathic essential subluxated lenses that had lens washout, lens capsule removal, Artisan IOL implantation, and peripheral iridectomy. The indications for surgery were reduced visual acuity and monocular diplopia. The main outcome measures were postoperative refraction and change in best corrected visual acuity (BCVA).

Results: The postoperative follow-up ranged from 8 to 10 months. After surgery, the BCVA was 6/12 or better in the 3 cases that could be recorded. Visual acuity improved by 2 or more Snellen lines in all 4 eyes. The postoperative spherical equivalent was within ± 1.00 diopter in all cases. No significant postoperative complications were observed.

Conclusions: In 4 eyes with a subluxated crystalline lens, implantation of an Artisan aphakic IOL improved visual acuity. Studies with a larger number of patients and longer follow-up are necessary to confirm these results.

J Cataract Refract Surg 2004; 30:1977–1981 © 2004 ASCRS and ESCRS

Ectopia lentis can be congenital, developmental, or acquired. It can occur as an ocular manifestation of a systemic hereditary disorder such as Marfan's syndrome, homocystinuria, Weill-Marchesani syndrome, hyperlysinemia, sulfite oxidase deficiency, and Ehlers-Danlos syndrome. It can also occur as an isolated anomaly (simple, essential, familial, or idiopathic ectopia lentis) that is usually inherited as an autosomal dominant trait.

Findings associated with crystalline lens subluxation include refractive changes and high astigmatism. The movement of the subluxated lens may cause marked visual disturbances and amblyopia. Potential complications of ectopia lentis include cataract and displacement of the lens into the anterior chamber or vitreous. Dislocation of the lens into the anterior chamber can damage the corneal endothelium and induce pupillary block and angle-closure glaucoma; dislocation into the vitreous can induce retinal detachment.^{1,2}

Intracapsular and extracapsular extraction of the lens, lens washout, and more recently pars plana lensectomy and vitrectomy are the current options for managing a subluxated lens.^{1,3} Anterior chamber or scleral-fixated posterior chamber intraocular lenses (IOLs) are usually implanted at surgery.

Another alternative is Artisan® (Ophtec) aphakic IOL implantation. This lens has been successfully implanted in children with congenital cataract,⁴ in children with myopic anisometropic amblyopia,^{5,6} and in adults with a subluxated lens.⁷

Accepted for publication January 12, 2004.

From the Ophthalmology Department, Soroka University Medical Center, Ben-Gurion University of the Negev, Beer-Sheva, Israel.

None of the authors has a financial or proprietary interest in any material or method mentioned.

Presented at the Second International Symposium on Refractive and Corneal Surgery, Dead Sea, Israel, May 2003.

Reprint requests to Jaime Levy MD, Department of Ophthalmology, Soroka University Medical Center, PO Box 151, Beer-Sheva 84101, Israel. E-mail: levy_jaime@hotmail.com.

To our knowledge, there are no reports in the literature of the use of aphakic Artisan IOLs in children with a subluxated lens. We describe our experience with aphakic Artisan IOL implantation in 3 children (4 eyes) with essential (idiopathic) subluxated lenses.

Patients and Methods

Three children with subluxated crystalline lenses were examined in the outpatient clinic at Soroka University Medical Center between June 2001 and June 2003. Patients were referred for poor or variable visual acuity. Medical history was recorded from the child's parents and included a detailed family history. A pediatrician examined the children for systemic anomalies.

Ophthalmic Examination

All patients had a full eye examination that included distance visual acuity measurement using a Snellen or illiterate "E" chart, cycloplegic refraction, keratometry, biometry, slitlamp evaluation of the anterior segment and the lens subluxation, intraocular pressure (IOP) measurement with a Goldmann or Tono-Pen® (Medtronic Solan) tonometer, and posterior segment evaluation. Photographs of the subluxated lens were taken when possible. Preoperative and postoperative endothelial counts were attempted in all cases.

Criteria for Surgery

Using the criteria of Halpert and BenEzra,¹ surgery was performed if 1 or more of the following were observed: monocular diplopia, distance best corrected visual acuity (BCVA) worse than 6/12, and variable refraction or variable BCVA measurements caused by progressive subluxation of the lens and bisection of the pupil. No eye had dislocation of the subluxated lens into the anterior chamber or vitreous or a cataractous lens.

Intraocular Lens

All eyes had implantation of an Artisan aphakic IOL with a 5.4 mm optic (model 205). The IOL power needed for emmetropia was calculated by the manufacturer before surgery by inserting the spherical equivalent (SE) refraction, keratometry, and anterior chamber depth into the van der Heijde formula. The IOLs were available in power increments of 0.50 diopter (D). The surgeon chose a lens power close to the power needed for emmetropia.

Surgical Technique

Surgery was performed using general anesthesia. A standard 6.0 mm sclerocorneal tunnel was prepared at the 12 o'clock position. Two paracenteses were placed at 10 o'clock and 2 o'clock. The anterior chamber was filled with sodium hyaluronate 2.3% (Healon®5). A minicapsulorhexis was cre-

ated and hydrodissection performed. The lens material was aspirated with a cannula connected to a 5 mL syringe with an anterior chamber maintainer. Healon 5 was injected to separate the posterior capsule from the anterior hyaloid face. The complete capsular bag was pulled out through the tunnel with a forceps. Acetylcholine was injected into the anterior chamber to constrict the pupil. If vitreous was seen in the anterior chamber, anterior vitrectomy was performed. An Artisan aphakic IOL was inserted in the anterior chamber with a forceps and fixated to the iris with enclavation needles. A peripheral iridectomy was performed at the 12 o'clock position. The corneoscleral wound was closed with 3 interrupted 10-0 nylon sutures, and the viscoelastic material was manually aspirated. Gentamicin 20 mg with betamethasone 3 mg was injected subconjunctivally immediately after surgery. Chloramphenicol ointment was applied to the eye.

Postoperative Care and Outcome Measures

Postoperatively, dexamethasone and chloramphenicol drops were used 4 times a day during the first 4 weeks. The dexamethasone drops were then tapered over 4 weeks. Patients were followed at the outpatient clinic. The BCVA was recorded. Cycloplegic refraction, slitlamp examination of the anterior and posterior segments, IOP measurement, and slitlamp photography of the IOL were also performed. Postoperative complications were recorded. The outcome measures were the BCVA and change in Snellen lines of BCVA.

Results

Four eyes (3 children) had Artisan aphakic IOL implantation for a subluxated lens. Table 1 shows the age at surgery, reason for surgery, preoperative and postoperative refractions and BCVAs, Artisan IOL power, change in Snellen lines of BCVA, endothelial cell count at the last-follow-up visit, intraoperative and postoperative complications, and length of follow-up.

All 3 patients had idiopathic subluxated lenses. The age at surgery ranged between 4 years and 11 years. All the patients were followed for a minimum of 8 months. The reason for surgery was a BCVA worse than 6/12 in 3 cases, monocular diplopia in 2 cases, and variable cycloplegic refraction measurements in 1 case. Before surgery, the SE ranged between -2.50 D and -23.00 D. After surgery, the SE was within ± 1.00 D in all 4 eyes. Three eyes required an anterior vitrectomy during surgery. No significant iritis, IOP elevation, IOL decentration, or irregular pupil was observed postoperatively. Three children were able to cooperate during postoperative refraction; the BCVA was 6/12 or better in all

Table 1. Summary of preoperative and postoperative data.

Parameter	Patient 1		Patient 2		Patient 3	
	RE	LE	RE	LE	RE	LE
Age at surgery	6 y 9 mo	6 y 8 mo	11 y 10 mo	—	4 y 1 mo	—
Reason for surgery	BCVA <6/12 Mono diplopia	BCVA <6/12 Mono diplopia	BCVA <6/12	—	Variable refraction	—
Spherical equivalent (D)						
Preop	-8.00	-8.00	-2.50	—	-23.00	—
Postop	-0.37	+0.50	-0.25	—	+0.75	—
Postop refraction (D)	+ 0.25 - 0.75 × 26	+1.00 - 1.00 × 130	+0.50 - 1.50 × 120	—	+1.25 - 1.00 × 76	—
BCVA						
Preop	6/15	6/15	6/30	—	NR/PC	—
Postop	6/9 ⁺¹	6/9 ⁺³	6/12	—	PC; >6/36	—
IOL power (D)	21.5	21.0	19.0	—	8.0	—
Intraop complications	Vitreous in AC	None	Vitreous in AC	—	Vitreous in AC	—
Specular microscopy						
Mean cells/mm ² ± SD	2264 ± 50	2741 ± 50	2894 ± 87	2901 ± 22	3693 ± 130	3246 ± 43
Postop time (mo)	9	10	8	—	8	—
Change in Snellen lines of BCVA	+2	+2	+3	—	≥+3	—
Follow-up (mo)	9	1	8	—	8	—

AC = anterior chamber; BCVA = best corrected visual acuity; LE = left eye; Mono diplopia = monocular diplopia; NR = not recordable; PC = poor cooperation; RE = right eye

cases. All 4 eyes gained a minimum of 2 Snellen lines of BCVA.

Figures 1 and 2 show the preoperative and postoperative appearance, respectively, of patient 1.

Discussion

Subluxated lenses are a challenge to the surgeon. Among the modern options for managing subluxated

lenses is performing a pars plana lensectomy with vitrectomy instruments. Using this method, Halpert and Ben-Ezra¹ observed only 1 case of retinal detachment in 59 eyes of children with subluxated lenses; the detachment appeared 2 years after surgery. Most of the eyes (88%) had an improvement of 2 or more Snellen lines of BCVA. However, the pars plana lensectomy requires 2 or 3 sclerotomies and must be performed by an experienced retina surgeon; in addition, damage to the periph-

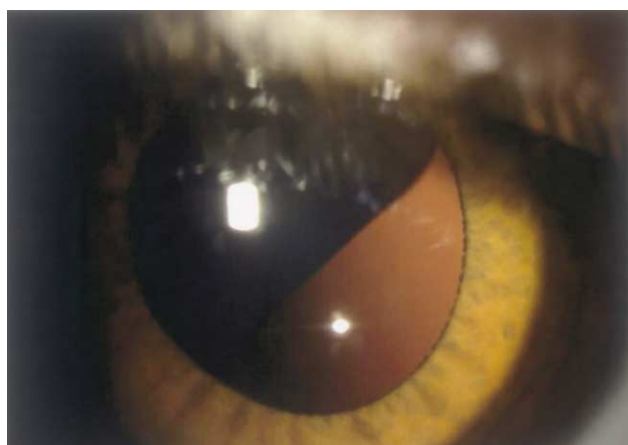


Figure 1. (Lifshitz) A preoperative photograph of the right eye of patient 1 shows the subluxated crystalline lens.

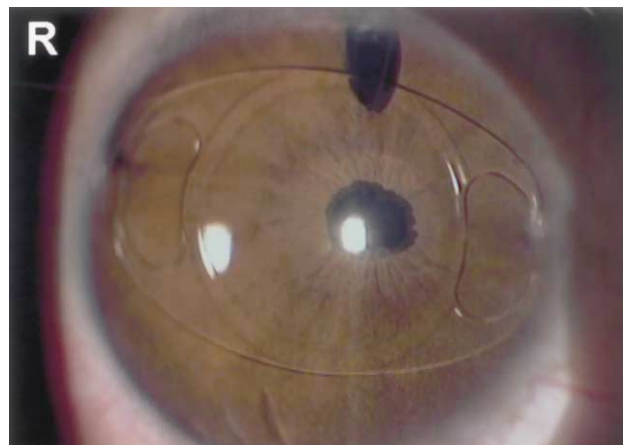


Figure 2. (Lifshitz) The right eye of patient 1 after Artisan aphakic IOL implantation.

eral retina can occur. At the time of Halpert and BenEzra's study in 1996, IOL implantation in children with ectopia lentis was a matter of debate; eyes remained aphakic and were treated postoperatively with contact lenses or glasses. In 2000, Siganos and coauthors³ described 4 cases of intracapsular clear lens cryoextraction and anterior chamber or scleral-fixated posterior chamber IOL implantation in adults. They suggest that modern cataract surgery with IOL implantation is a good option in selected cases of subluxated lenses. Furthermore, removing the subluxated lens via a limbal incision using modern techniques is associated with a low complication rate.

Since its invention by Jan Worst in 1986, the Artisan IOL, formerly known as the Worst-Fechner claw lens, has been largely used in cataract surgery, especially in the Netherlands, India, and Pakistan. In recent years, a variation of the original model has been used to correct high refractive errors in phakic adults.⁸⁻¹⁰ However, there are few reports of Artisan aphakic IOL implantation in children. Van der Pol and Worst⁴ describe the use of Artisan aphakic IOLs in children with congenital, traumatic, or developmental cataract. Their results were similar to those in other reports in which posterior chamber IOLs were used. The authors suggest that Artisan aphakic IOLs are easy to remove and implant after the removal of another type of IOL. To our knowledge, there are no reports of Artisan aphakic IOL implantation during surgery for subluxated lenses in children. Gabor⁷ describes their use in adults with subluxated lenses.

In our study, all 4 eyes gained 2 or more Snellen lines of BCVA. The only intraoperative complication was the appearance of vitreous in the anterior chamber in 3 cases, requiring anterior vitrectomy. In 1 patient, the use of the highly viscous and cohesive Healon5 was successful in pushing back the vitreous face and no anterior vitrectomy was needed. No postoperative complications were observed. In reports of Artisan phakic IOLs in adults,⁸⁻¹⁰ the most frequent complications were an irregular pupil (0.4% to 1.2%), transient corneal edema (0.8% to 1.4%), transient IOP elevation (1.4%), and IOL decentration (in up to 2%). At the end of the follow-up period in our study, the IOL was well-centered, the pupil was regular, and the eye was quiet with no sign of iritis in all 4 cases.

An area of concern with Artisan IOL implantation is endothelial cell loss. In our study, all 3 patients were too uncooperative for a preoperative endothelial count. In the cases of unilateral IOL implantation (patients 2 and 3), the comparison between the operated eye and unoperated eye at the last follow-up visit (8 months after surgery) did not show cell loss. The mean cell count in the operated eye was $2894 \text{ cells/mm}^2 \pm 87$ (SD) in patient 2 and $3693 \pm 130 \text{ cells/mm}^2$ in patient 3. The mean in the unoperated eye was $2901 \pm 22 \text{ cells/mm}^2$ and $3246 \pm 43 \text{ cells/mm}^2$, respectively. Menezo and coauthors¹¹ report that the largest reduction in endothelial cell density and the most significant changes in morphology (ie, increase in the coefficient of variation in cell size and decrease in the percentage of hexagonal cells) occurred in the first 6 months postoperatively. At later follow-ups (up to 4 years), the rate of cell loss diminished and the hexagonality and coefficient of variation tended to return to preoperative levels. Budo and coauthors⁸ report an initial endothelial cell loss of 4.8% 6 months postoperatively, which decreased to 0.7% at 3 years. Basti et al.¹² report an endothelial cell loss of approximately 6% in children 24 to 36 months after extracapsular cataract extraction and posterior chamber IOL implantation. They found no significant differences when they compared these results with results in adult cataract patients. Although long-term data are not available, the results in these studies indicate that significant endothelial cell loss occurs during surgery but there is no significant continuous cell loss. A longer follow-up is needed to assess endothelial cell loss in our 3 patients.

In conclusion, implantation of an Artisan aphakic IOL to correct the refractive error caused by a subluxated lens was relatively easy to perform in all 4 eyes in our study. We believe it is a better option than a scleral-fixated or angle-fixated IOL or leaving the child aphakic with subsequent treatment with glasses or contact lenses. Studies with a larger cohort and over a longer period are needed.

References

1. Halpert M, BenEzra D. Surgery of the hereditary subluxated lens in children. *Ophthalmology* 1996; 103:681-686

2. American Academy of Ophthalmology. Basic and Clinical Science Course. Section 11: Lens and Cataract. San Francisco, CA, American Academy of Ophthalmology, 2002; 37
3. Siganos DS, Siganos CS, Popescu CN, Margaritis VN. Clear lens extraction and intraocular lens implantation in Marfan's syndrome. *J Cataract Refract Surg* 2000; 26: 781–784
4. van der Pol BAE, Worst JGF. Iris-claw intraocular lenses in children. *Doc Ophthalmol* 1996–1997; 92:29–35
5. Chipont EM, García-Hermosa P, Alió JL. Reversal of myopic anisometropic amblyopia with phakic intraocular lens implantation. *J Refract Surg* 2001; 17:460–462
6. Saxena R, van Minderhout HM, Luyten GPM. Anterior chamber iris-fixated phakic intraocular lens for anisometropic amblyopia. *J Cataract Refract Surg* 2003; 29:835–838
7. Gabor R. Artisan IOL after phacoemulsification in subluxated lens [letter]. *J Cataract Refract Surg* 2002; 28:2064
8. Budo C, Hessloehl JC, Izak M, et al. Multicenter study of the Artisan phakic intraocular lens. *J Cataract Refract Surg* 2000; 26:1163–1171
9. Maloney RK, Nguyen LH, John ME. Artisan phakic intraocular lens for myopia; short-term results of a prospective, multicenter study; the Artisan Lens Study Group. *Ophthalmology* 2002; 109:1631–1641
10. Landesz M, Worst JGF, van Rij G. Long-term results of correction of high myopia with an iris claw phakic intraocular lens. *J Refract Surg* 2000; 16:310–316
11. Menezo JL, Cisneros AL, Rodriguez-Salvador V. Endothelial study of iris-claw phakic lens: four year follow-up. *J Cataract Refract Surg* 1998; 24:1039–1049
12. Basti S, Aasuri MK, Reddy S, et al. Prospective evaluation of corneal endothelial cell loss after pediatric cataract surgery. *J Cataract Refract Surg* 1998; 24:1469–1473