

Ultrasound biomicroscopy study of the Verisyse aphakic intraocular lens combined with penetrating keratoplasty in pseudophakic bullous keratopathy

Jean-Jacques Gicquel, MD, MS, Sébastien Guigou, MD, Riad A. Bejjani, MD, PhD, Benoit Briat, MD, Pierre Ellies, MD, Paul Dighiero, MD, PhD

PURPOSE: To evaluate anterior segment modifications after penetrating keratoplasty (PKP), previous anterior chamber intraocular lens (IOL) removal, and Verisyse IOL (AMO) implantation over the iris or under the iris for the treatment of pseudophakic bullous keratopathy (PBK) using ultrasound biomicroscopy.


SETTING: Department of Ophthalmology, Poitiers University Hospital, Poitiers, France.

METHODS: A prospective randomized comparative case series included 27 patients (27 eyes) with PBK who had PKP and implantation of a Verisyse VRSA54 aphakic IOL. The IOL was implanted over the iris in 13 patients (Group A) and under the iris in a reversed position in 14 patients (Group B). Ultrasound biomicroscopy scans 6 months after surgery measured central anterior chamber depth (ACD), iris thickness (IT), distance of the haptics from the corneal endothelium (CED), distance of the haptics from the ciliary body (CBD), angle opening distance (AOD) 500 μm from the scleral spur (AOD500) and the iridocorneal angle θ on the 4 o'clock meridian lines (AOD3; AOD9; AOD12; AOD6/ θ 12, θ 6, θ 3, θ 9).

RESULTS: No significant difference was found in IT, CBD, or AOD12 between Group A and Group B ($P > .05$). In Group B, the mean ACD was deeper by approximately 55% ($P = .008$); CED3 was larger by 69% ($P = .0162$), CED9 by 80% ($P = .0128$), AOD3 by 57% ($P = .0309$), AOD9 by 140% ($P = .0057$), and AOD6 by 44% ($P = .0399$); and θ 3 was wider by 52% ($P = .046$), θ 9 by 123% ($P = .0068$), θ 12 by 50% ($P = .0492$), and θ 6 by 81% ($P = .0237$).

CONCLUSION: Ultrasound biomicroscopy showed that in eyes that had PKP with Verisyse IOL enclavation to the posterior plane of the iris, which involved posterior translation of the iridal plane, the ACD was significantly deeper and the CED and AOD were significantly larger than in eyes with anterior enclavation of the IOL.

J Cataract Refract Surg 2007; 33:455–464 © 2007 ASCRS and ESCRS

 Indicates Online Video

The ideal position of the intraocular lens (IOL) after extracapsular cataract extraction is behind the iris plane. However, if there is a major capsule tear, the IOL must be sutured to the sclera or fixated in the anterior chamber because there are not enough capsular bag remnants for sulcus implantation. The use of angle-supported anterior chamber IOLs with iridocorneal angle (ICA) fixation may cause endothelial cell loss and pseudophakic bullous keratopathy (PBK). Complications caused by transscleral sulcus-sutured IOLs include chronic inflammation, IOL-iris contact, IOL decentration, pigmentary

dispersion, high aqueous flare, vitreous incarceration, and best corrected visual acuity (BCVA) loss resulting from cystoid macular edema.¹

The next-generation refractive iris-fixated anterior chamber IOLs maintain sufficient space between the IOL and the endothelium so as not to harm the endothelium in phakic and aphakic eyes in the absence of penetrating keratoplasty (PKP).² Verisyse (AMO) are single-piece poly(methyl methacrylate) iris-claw anterior chamber IOLs designed primarily for additive refractive surgery.³

We wondered whether the aphakic version of the Verisyse IOL (VRSA 54) would not be as satisfactory when implanted in the anterior chamber in combination with PKP for PBK. Thus, the aim of this study was to find an improved surgical technique that would better respect the anterior segment anatomy. Two groups of patients had combined surgery, 1 with the iris-fixated IOLs implanted in the anterior chamber and enclavated over the iris plane (classic technique) and the other with the IOL placed under the iris and enclavated to its posterior plane. We compared the quantitative changes in anterior segment configuration using the ultrasound biomicroscopy (UBM) technique developed by Pavlin et al.⁴ in 1990 to determine which technique was more appropriate for PBK surgical treatment.

PATIENTS AND METHODS

The study consisted of a prospective comparative randomized case series of 27 patients (27 eyes) who had PKP for PBK followed by Verisyse IOL implantation between September 2002 and July 2004. Approval of the Institutional Review Board of the University of Poitiers, Jean Bernard University Hospital, Poitiers, Poitou-Charente, France, was obtained, and informed consent was signed by all patients in the study, according to French regulations (<http://www.agmed.sante.gouv.fr/hm/5/essclindm.htm> [online]. Accessed: September 19, 2006).

Inclusion criteria were PBK, previous implantation of an angle-supported IOL, and preoperative BCVA worse than 20/100. Patients with major extensive goniosynechias in whom goniosynechialysis may have compromised iris integrity or who had insufficient iridal support (iris damage after phacoemulsification) were excluded, as were those with limbal stem cell disease and dysfunction.⁵

Surgical technique

All surgery was done by the same surgeon (P.D.). All patients had PKP with systematic open-sky

removal of the formerly implanted angle-supported IOL followed by anterior vitrectomy associated with synechiolysis of the angle and/or iridoplasty to obtain a centrally placed pupil. Eyes were trephinated with a Hanna trephine. The corneal button was then cut out with scissors. An oversized graft diameter of 8.25 mm was chosen (8.00 mm for the recipient bed). Before implantation of the Verisyse IOL, the pupil was constricted with intracameral acetylcholine (Miochol). In all cases, the Verisyse IOL was enclavated, trapping a fraction of the midperipheral iris within the haptics (haptics at 3 o'clock and 9 o'clock) using an open-sky approach over the iris (Group A, 13 eyes) or under the iris (Group B, 14 eyes).


In Group A, once the pupil was centered in the anterior chamber, a fold of the peripheral iris was grasped with a forceps and the IOL was pressed over the top. The procedure was repeated with the other haptic. In Group B, the IOL was enclavated in a reverse position by guiding it through the pupil with a posterior vaulted orientation (avoiding rubbing against the iris) into the posterior chamber and lifted against the iris and centered before being trapped on the iris with a Sinsky-type manipulator. Previously performed anterior vitrectomy helped IOL vaulting, and no iridectomy was necessary. The donor corneal button was then sutured to the recipient bed with 10-0 nylon interrupted sutures that were not to be removed before 12 months after surgery.

All patients received a postoperative regimen of topical dexamethasone and neomycin 4 times a day for 1 month. This treatment was tapered over 4 to 6 months.

Corneal endothelial cell count

Six months and 1 year after surgery, specular microscopy of the graft endothelium was performed using a noncontact specular microscope (Topcon SP-2000P).

Ultrasound biomicroscopy

In both groups, postoperative UBM was performed to accurately study the position of the IOL and the anatomical changes in anterior chamber structures. Ultrasound biomicroscopic measurements were taken with a UBM P40 (Paradigm Medical) using a 50 MHz transducer, giving 5.0 mm of tissue penetration and 50 μ m resolution. The examination technique was described in detail by Pavlin and Foster⁶ ( Video 1). The same examiner did the examinations using topical anesthesia (oxybuprocaine 0.4%), a blepharostat, and an orbital cup.⁷ All UBM examinations were done 6 months after surgery and recorded on videotape for further analysis.

Accepted for publication November 15, 2006.

From the Department of Ophthalmology (Gicquel, Guigou, Ellies, Dighiero), Poitiers University Hospital, Poitiers, and a private practice (Briat), La Rochelle, France; the Department of Ophthalmology (Bejjani), Hôtel Dieu de France, Beirut, Lebanon.

No author has a financial or proprietary interest in any material or method mentioned.

Corresponding author: P. Dighiero, MD, Ophthalmology Department, Poitiers University Hospital, C.H.U Jean Bernard, 2 rue de la Milétrie, BP 577- 6021, Poitiers, France. E-mail: pauldighiero@aol.com.

Eyes were examined using the same protocol, and measurements were taken using the cursors provided by the UBM software. Examinations were performed under constant room illumination (50 lux). The patients were asked to fixate on a ceiling target.

A central sagittal (vertical) section through the corneal apex and IOL was taken to verify that the IOL was well centered and measure the distance between the corneal endothelium and the anterior face of the IOL, corresponding to the anterior chamber depth (ACD).

Four transversal radial sections following the 4 main meridians (3 o'clock, 6 o'clock, 9 o'clock, and 12 o'clock) were taken. These allowed measurement of the minimum distance between the IOL haptic and endothelium (corneal endothelium distance [CED]) and between the IOL haptic and the ciliary body (ciliary body distance [CBD]) at the 3 o'clock and 9 o'clock positions (CBD3 and CBD9, respectively). The angle opening distance (AOD) 500 μ m from the scleral spur (AOD500) in millimeters and the iridocorneal angle θ (ICA) in degrees were measured along the 4 main meridians (AOD3 AOD6, AOD9, and AOD12, respectively, and θ 3, θ 6, θ 9, and θ 12, respectively) (Figure 1). The ICA is defined as an angle formed with the apex at the iris recess and the arms passing through the point on the meshwork 500 μ m from the scleral spur to the point on the iris perpendicularly opposite. Pavlin and Foster⁶ define AOD as the length of a line drawn from the point on the endothelial surface 500 μ m anterior to the scleral spur to the iris surface perpendicular to the corneal endothelial surface.

Statistical analysis

Statistical analysis was performed using SAS for Windows (version 8.0, SAS Institute). Quantitative variables were compared using the nonparametric 2-tailed Wilcoxon test with an approximation to a *t* distribution. Qualitative variables were analyzed using the 2-tailed chi-square test when applicable or with the nonparametric 2-tailed Fisher test. A *P* value of 0.05 or less was considered statistically significant.

RESULTS

Preoperative and perioperative data

Group A comprised 7 men and 6 women and Group B, 9 men and 5 women. The mean age was 79.4 years \pm 6.7 (SD) (median 77 years) and 79.5 \pm 8.33 years (median 81 years), respectively. There were 8 right eyes and 5 left eyes in Group A and 7 right eyes and 7 left eyes in Group B. There was no statistically significant between-group difference in sex ratio (*P* = .058), age (*P* = .904), or laterality (*P* = .11).

The angle-supported anterior chamber IOL was a significant cause of corneal endothelium failure in all patients. Vitreous loss was recorded in all patients. The ACD measured during preoperative ultrasound biometry was not statistically different between the 2 groups (*P* = .3); the mean was 3.22 \pm 0.11 mm (range 3.05 to 3.42 mm) in Group A and 3.17 \pm 0.13 mm (range 2.95 to 3.45 mm) in Group B. Iridoplasty to give the best IOL centration was necessary in 2 patients in Group A and 3 in Group B.

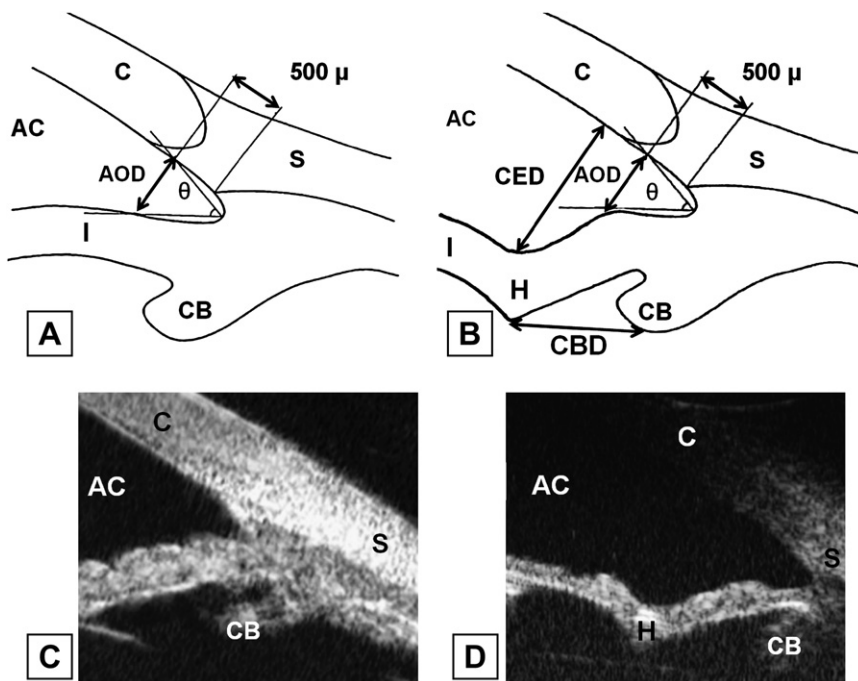


Figure 1. Schematic representation of a normal ICA (θ) in a phakic eye (A) and its appearance in UBM (C). In UBM, the cornea (C), anterior chamber (AC), and iris (I) are visible. Schematic representation of the ICA at 3 o'clock and 9 o'clock after implantation of an Artisan IOL enclavated under the iris (B) and its appearance in UBM. The same anatomical attributes are visible. A modified aspect of the iridocorneal angle and new angle caused by Artisan haptic enclavation (H) were noted (AOD = angle opening distance; CBD = distance between the haptic and ciliary body; CED = distance between the haptic and endothelium; S = scleral spur).

Complications

No intraoperative complication was recorded. In Group B, partial disenclavation of the IOL (Figure 2, A) occurred in 1 patient (#16) 3 weeks after surgery. (The iris remained entrapped in the 9 o'clock haptic and the 3 o'clock haptic, and the IOL body was sinking into the vitreous.) Reenclavation and complementary anterior vitrectomy requiring small 1.5 mm incisions were performed using tetracaine 0.5% topical anesthesia in the outpatient ophthalmology department. The patient recovered with no complications. Two cases of IOL decentration (Figure 2, B) were observed in both groups ($P = 1$). In 3 patients in Group A and 4 in Group B, there was onset of a pupil ovalization (Figure 2, C) ($P = 1$). There were 2 cases of pigmentary dispersion in Group B ($P = .48$). In 3 patients in Group A, the haptic was in contact with the corneal endothelium, although this was not observed in Group B. Postoperative iridal synechias were noted in 7 patients in Group A and 3 patients in Group B ($P = .12$).

Endothelial cell loss

Six month after surgery, the corneal endothelial cell count was not significantly different between Group A and Group B; the respective means were 1460 ± 133 cells/mm² (range 1250 to 1705 cells/mm²) and 1478 ± 198 cells/mm² (range 950 to 1755 cells/mm²) ($P = .78$). At 1 year, however, the endothelial cell count was significantly lower in Group A (mean

1185 ± 222 cells/mm²; range 855 to 1535 cells/mm²) than in Group B (mean 1426 ± 215 cells/mm²; range 880 to 1745 cells/mm²) ($P = .008$).

Ultrasound biomicroscopy measurements

Table 1 shows the UBM examination results 6 months after surgery. The mean ACD was deeper by about 55% ($P = .008$) (Figures 3 and 4). The mean CED3 was larger by 69% ($P = .0162$), CED9 by 80% ($P = .0128$), AOD3 by 57% ($P = .0309$), AOD9 by 140% ($P = .0057$), and AOD6 by 44% ($P = .0399$) in Group B than in Group A. Also, θ_3 was wider by 52% ($P = .046$), θ_9 by 123% ($P = .0068$), θ_{12} by 50% ($P = .0492$), and θ_6 by 81% ($P = .0237$) in Group B than in Group A (Figure 3).

The mean CED3 and CED9 were significant larger in Group B than Group A (CED3 + 69%, $P = .0162$; CED9 + 80%, $P = .0128$) (Figure 3). In Group A, 2 patients had permanent contact between 1 haptic and the corneal endothelium (Figure 4) and 1 patient between both haptics and the corneal endothelium. No contact was observed in Group B.

The mean AODs were significantly larger in Group B than in Group A for all but the 12 o'clock meridian (+57% AOD3, $P = .0309$; +44% AOD6, $P = .0399$; +140% AOD9, $P = .0057$). The mean AOD at 12 o'clock was 50% larger in Group B than in Group A, but the difference was not statistically significant ($P = .069$) (Figure 3).

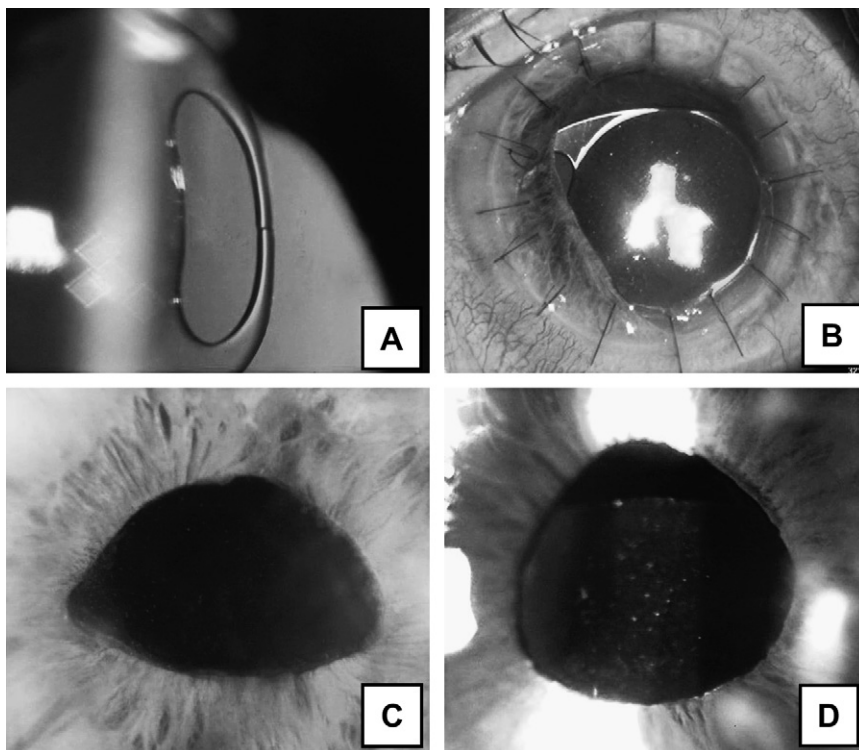


Figure 2. Slitlamp view of the complications secondary to the enclavation method. A: Partial disenclavation: The 9 o'clock haptic is unclipped in the right eye in patient 3 (Group B). B: Decentration of the retropupillary-implanted IOL in patient 5 (Group B). C: Three o'clock/9 o'clock pupil ovalization in patient 7 (Group B). D: Pigmentary dispersion on the anterior optic of the retropupillary-implanted IOL in patient 2 (Group B).

Table 1. Results of UBM measurements.

Parameter	Mean		SD		Minimum		Maximum		Median	
	Group A	Group B	Group A	Group B	Group A	Group B	Group A	Group B	Group A	Group B
ACD (mm)	1.857	2.883	0.439	0.773	1.16	1.21	2.5	3.88	1.98	3.01
AOD500 (mm)										
12 o'clock	0.289	0.434	0.212	0.159	0	0.15	0.66	0.72	0.34	0.47
6 o'clock	0.323	0.467	0.294	0.110	0	0.29	1.01	0.61	0.35	0.46
3 o'clock	0.334	0.525	0.210	0.216	0	0.12	0.66	0.8	0.38	0.59
9 o'clock	0.221	0.533	0.215	1.89	0	0.18	0.68	0.78	0.22	0.58
ICA (degrees)										
012	29.794	44.877	21.927	16.032	0	15.2	55.9	71.05	41.02	49.54
06	25.931	47.085	23.469	11.1	0	26.05	61.5	65.12	31.87	48.57
03	35.66	53.416	18.96	21.288	0	15.06	65.3	87.58	42.4	58.67
09	24.178	54.01	22.517	20.36	0	19.11	68.06	88.91	27.6	59.58
CED (mm)										
3 o'clock	0.862	1.462	0.548	0.472	0	0.49	1.74	2	1.01	1.67
9 o'clock	0.766	1.384	0.554	0.401	0	0.72	1.6	2	0.94	1.37
CBD (mm)										
3 o'clock	1.795	1.415	0.723	0.465	0.81	0.62	3.03	2.14	1.7	1.33
9 o'clock	1.978	1.437	0.953	0.478	0.66	0.61	3.89	2.11	1.84	1.57
IT (mm)										
3 o'clock	0.335	0.313	0.090	0.065	0.22	0.21	0.53	0.42	0.32	0.31
9 o'clock	0.358	0.357	0.064	0.086	0.28	0.21	0.52	0.48	0.35	0.37

ACD = anterior chamber depth; AOD500 = angle opening distance 500 μ m from the scleral spur; CBD = distance from haptic to the body; CED = distance from haptic to corneal endothelium; ICA = iridocorneal angle; IT = iris thickness

The mean ICA was significantly wider in Group B than in Group A at all clock meridians (+52% 03, $P = .046$; +81% 06, $P = .0237$; +123% 09, $P = .0068$; +50% 012, $P = .0492$) (Figure 5). The difference between the 2 groups in mean CBD was not statistically significant (CBD3, $P = .274$; CBD9, $P = .227$). The mean iris thickness measured on the enclavation sites was not significantly different between the 2 groups (3 o'clock; $P = .665$; 9 o'clock, $P = .885$).

DISCUSSION

The first study of retropupillary fixation of an iris-claw IOL in aphakia was published by Rijnveld et al.⁸ In the study, 12 patients (mean age 77 years) had anterior fixation and 7 had implantation behind the iris (mean follow-up 11.8 months). The authors found iridal synechias in 11% of patients who had anterior fixation and in 5% of patients who had retropupillary fixation. Three cases of pigmentary dispersion were observed in 18 retropupillary implantations, and no cases were observed in patients with anterior chamber iris-claw IOLs, although the difference was not statistically significant. Rijnveld et al. suggest it is preferable to use the anterior fixation technique.

Kanellopoulos⁹ studied Artisan iris-fixed IOL implantation associated with PKP for managing aphakic

keratopathy in 11 patients (mean age 80.5 years). Good refractive results were obtained, although 1 decentration and 1 hyphema associated with high intraocular pressure (IOP) were reported; both were transient, however. Kanellopoulos considered the open-sky procedure to be short and simple. He suggested that the absence of sutures and limited IOL manipulation explained the low rate of posterior segment complications. However, he stressed that endothelial trauma was possible during the surgical procedure and there was risk for anterior synechias on the limiting ring. In our study, we observed more iridal synechias than Rijnveld et al.⁸ in Group A but fewer cases of pigmentary dispersion in Group B. Rijnveld et al. concluded that anterior enclavation was a superior technique. However, their patients' characteristics were not the same as those of our patients. Rijnveld et al. were studying patients with aphakia during PKP, which is different from patients in our study, who all required angle-supported anterior chamber IOL explantation. Mohr et al.¹⁰ published the second study on retropupillary iris-claw IOL fixation in 48 aphakic patients. No major complications were observed, and the new retropupillary technique was shown to be superior (simplicity, reliability, and best anatomical results) to other techniques. Although complications secondary to the enclavation method occurred, we found no

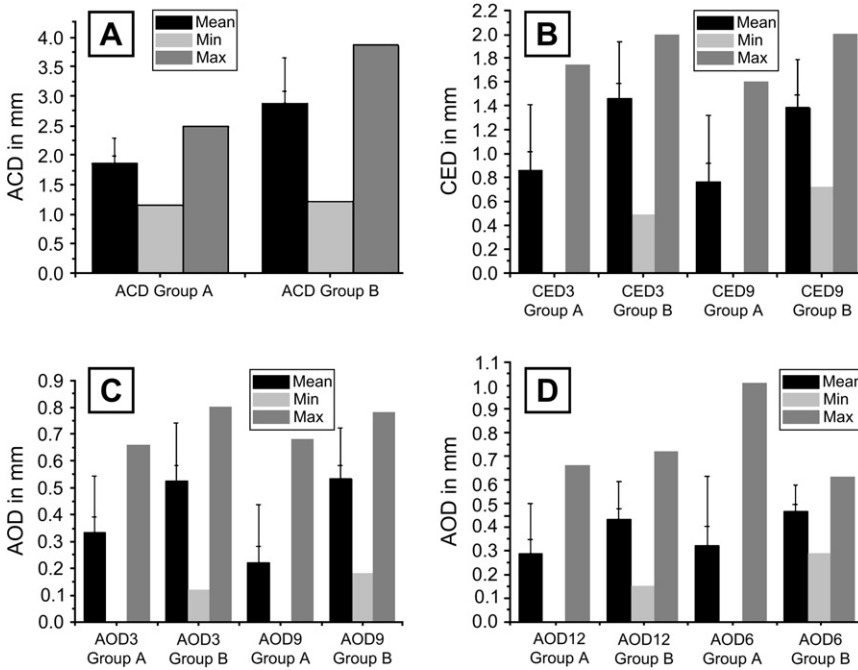


Figure 3. Graphic representation of UBM measurements in Group A and Group B. A: Anterior chamber depth in Group A (ACD Group A) and Group B (ACD Group B). B: Distance from the haptic to the endothelium at 3 o'clock in Group A (CED3 Group A) and Group B (CED3 Group B) and at 9 o'clock in Group A (CED9 Group A) and Group B (CED9 Group B). C: Angle opening distance at 3 o'clock in Group A (AOD3 Group A) and Group B (AOD3 Group B) and at 9 o'clock in Group A (AOD9 Group A) and Group B (AOD9 Group B). D: Angle opening distance at 12 o'clock in Group A (AOD12 Group A) and Group B (AOD12 Group B) and at 6 o'clock in Group A (AOD6 Group A) and Group B (AOD6 Group B).

significant difference between the 2 groups in the onset of a pupil ovalization. This is not a common complication, although it has already been reported after iris-claw IOL implantation¹¹ and is an acceptable complication considering the severity of the initial disease.⁸

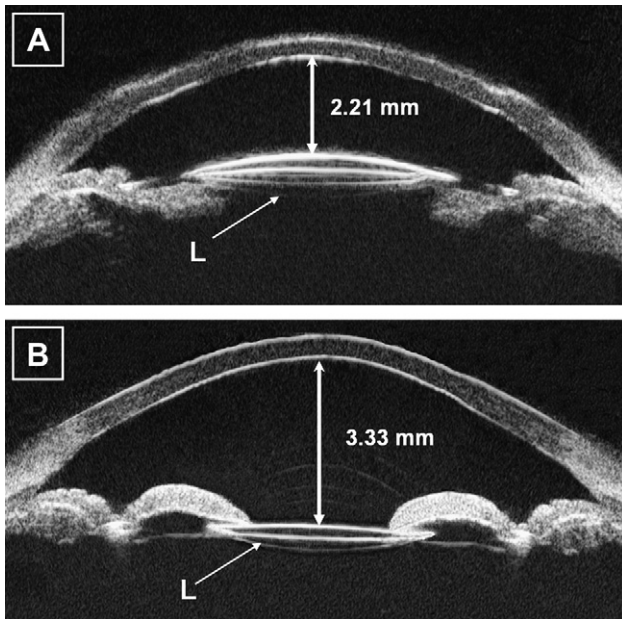


Figure 4. Postoperative composite of 2 longitudinal axial UBM echograms along the 3 o'clock/9 o'clock meridian line. A: The iris-claw Verisyse IOL (L) implanted over the iris in patient 3 (Group A). The IOL appears hyperechogenic. The chamber is 2.21 mm. B: Iris-claw Verisyse IOL (L) implanted under the iris in patient 6 (Group B) (mean anatomical result). The anterior chamber appears significantly deeper (3.33 mm).

The onset of pigmentary dispersion requires longer-term follow-up to evaluate whether it is secondary to the trauma from implantation or to chronic friction between the posterior face of the iris and the IOL and whether the patients develop secondary pigmentary glaucoma.¹² Intraocular lens decentration was the result of poor centration during surgery. These factors are responsible for a nocturnal halos vision (diffraction on IOL borders during mydriasis).

In Group B, 1 patient had a partial disenclavation (1 haptic) 8 months after surgery. This rare complication had been reported.^{13,14} Haptic repositioning is easily achieved through small incisions using local anesthesia. Posterior fixation has the advantage over anterior fixation because if 1 haptic becomes disenclavated (bilateral disenclavation has not been reported), no contact with the endothelium is possible.^{14,15} Of the 3 patients in Group A who had contact between the IOL and corneal endothelium, 2 refused surgery to reposition the IOL behind the iris. The third could not have additional surgery because of old age and poor health. This contact leads to unavoidable endothelial failure.¹⁶ From an optical viewpoint, this misplacement of the IOL leads to increased myopia, resulting in decreased visual acuity.

All complications associated with the retropupillary fixation technique seem acceptable considering the severity of the initial disease. However, the occurrence of contact between the IOL haptic and the corneal endothelium in Group A is unacceptable and can directly result in new corneal endothelial failure. The endothelial cell count data in our series showed a significant

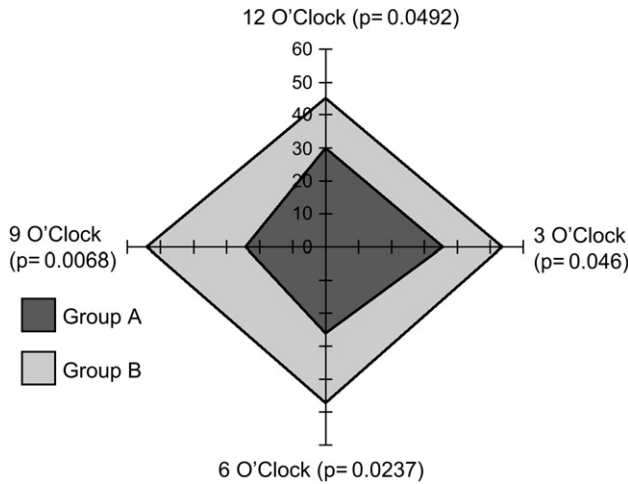


Figure 5. Iridocorneal angle θ 6 months after surgery in Group A and Group B.

difference in cell density between Group A and Group B after 1 year and greater mean cell loss (19.0% versus 3.7%, respectively) between 6 months and 1 year after surgery. Moshirfar et al.¹⁷ report 2 cases of Artisan phakic IOL implantation for correction of high myopia after PKP. They found no significant endothelial cell loss 6 months after surgery.

In contrast, in a 3-year follow-up of 36 eyes with an Artisan toric IOL, Tahzib et al.¹⁸ report endothelial cell loss (mean 21.2% between 6 months and 1 year) comparable to that in our Group A. The authors conclude that after iris-claw IOL implantation in phakic eyes with PKP, endothelial cell loss continues from 6 months to 3 years. In aphakic eyes without PKP, Güell et al.¹⁹ found a mean endothelial cell loss of 10.9% 3 years after Verisyse aphakic IOL implantation. Endothelial cell loss results in phakic eyes without PKP vary in the literature. Pop and Payette,²⁰ who studied the Artisan-Verisyse IOL for refractive surgery in phakic patients, and Bartels et al.,²¹ who performed a prospective study of 47 eyes with a toric phakic IOL for hyperopia and astigmatism, report no significant endothelial cell loss 1 year after surgery.

Menezo et al.²² report a mean endothelial loss of 6.6% 1 year after iris-claw IOL implantation. In a prospective clinical trial of 40 eyes of 23 patients with high myopia or hyperopia with an Artisan toric IOL, Tehrani and Dick²³ report a mean endothelial cell loss of 3.2% in the myopic group and 2.9% in the hyperopic group 3 years after surgery (both values greater than the physiological annual loss). In a study of phakic hyperopic patients, Saxena et al.²⁴ report iris complications including synechias, pigmentary dispersion, and pupil ovalization in 2 of 26 patients. They suggest that good endothelial tolerance is directly correlated

with ACD. These data confirm that the farther the Verisyse IOL is from the endothelium, the less the endothelial cell loss. Tehrani and Dick²⁵ recommend the use of a bolus of a high-viscosity ophthalmic viscosurgical device placed over the optic of the iris-fixed phakic IOL to separate it widely from the endothelium, decreasing the chance for endothelial damage during enclavation.

Ultrasound biomicroscopy measurements

The new generation of iris-claw IOLs (Artisan, Verisyse) has been studied by UBM only in refractive surgery in phakic patients. Pop et al.^{20,26} used UBM to study the anatomical characteristics of the Artisan IOL in hyperopic patients ($n = 4$) and myopic patients ($n = 3$). The ACD decreased by 28% to 34% and from 2.03 to 2.54 mm after IOL implantation. They did not report contact between the IOL and endothelium, nor were there cases of iridocorneal synechias. However, they report possible secondary pigmentary dispersion resulting from entrapment of the iris, although there were no cases of high postoperative IOP. Several analyses of normal, glaucomatous, phakic, cataract, and pseudophakic patients have been done using UBM.²⁷⁻³⁰

To our knowledge, there are no published studies of Verisyse morphology by UBM after PKP. Ultrasound biomicroscopy is used during the preoperative assessment to evaluate the difficulty of the surgery³¹ or, in particular, during the postoperative period to study the anatomical characteristics of phakic IOLs.²⁰ As with all ultrasound procedures, reproducibility and quality depend on the operator. The reproducibility of UBM echograms and their analysis has been studied by Yang, et al.,³² de Souza Filho et al.,³³ and Spaeth et al.³⁴ These 3 studies confirmed low interobserver and intraobserver variability and validated the method of Pavlin and Foster.⁶

In our study, there was a strongly significant difference between the groups in ACD, with the posterior technique having a 55% deeper mean ACD. Thus, posterior enclavation makes it possible to move the optical zone of Artisan-Verisyse IOLs away from the corneal endothelium. This increase in the ACD is the result of several factors: the reversed position of the arciform IOL, enclavation behind the iridal plane, and posterior translation of the entire iris. Anterior enclavation results in the optical zone and haptics being closer to the endothelium and may compromise the endothelial survival rate.²⁴ Ultrasound biomicroscopic analysis revealed permanent contact between the endothelium and 1 haptic in 2 patients and both haptics in 1 patient, all 3 in Group A. This major complication leads to medium-term graft failure (Figure 6).^{35,36} No contact

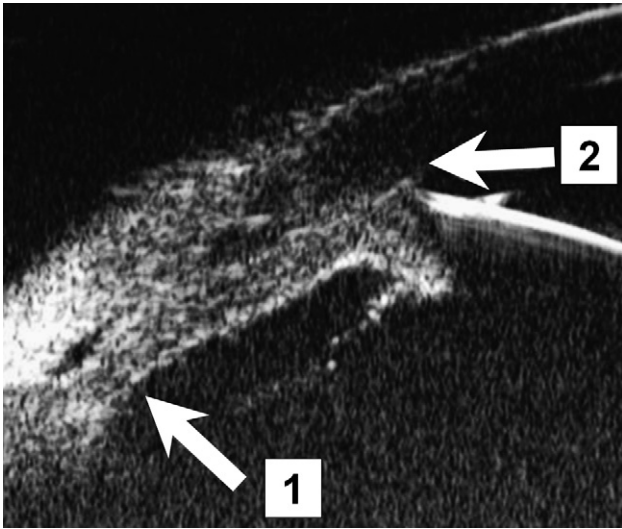


Figure 6. Ultrasound biomicroscopic image of the iridocorneal angle in patient 5 (Group A): angle closure (1) + haptic-corneal endothelium contact (2).

is possible between 1 haptic and the corneal endothelium with the posterior fixation technique used in Group B.

The CED measurements on the 3 o'clock and 9 o'clock meridian lines (at the most peripheral part of the IOL) were significantly different between the 2 techniques. Posterior enclavation increased the CED by a mean of 69% on the 3 o'clock meridian line and by a mean of 80% on the 9 o'clock meridian line. A larger CED is needed in PKP because the limiting ring (junction between the cornea of the receiver and the donor) is thicker in front of the haptic. This results in an additional risk for anterior synechias, as highlighted by Rijneveld et al.⁸ and Kanellopoulos.⁹ The increase in ACD and in the distance of the IOL haptics on the 3 o'clock and 9 o'clock meridian lines and the absence of endothelial contact in Group B are good prognosis factors.

The AOD500 and ICA measurements on the 4 meridian lines significantly differed except for AOD12, with the mean AOD500 being larger on average by

57% for AOD3, 44% for AOD6, and 140% for AOD9 and the iridocorneal angle being wider on average by 52% for θ ICA3, 81% for θ ICA6, 123% for θ ICA9, and 50% for θ ICA12. The increase in AOD and ICA along the 3 o'clock and 9 o'clock meridian lines is secondary to the mechanical traction of the haptics exerted on the iridal stroma. In Group B, the iridal plane was moved globally backward. The increase in the AOD500 was also seen on the 6 o'clock and 12 o'clock meridians, which were not enclavation zones but followed the posterior traction of the whole iris. In Group A, 23.07% of patients had an AOD500 equal to 0. This confirms the localized angle closure in eyes with haptic-endothelial contact. This was not observed in Group B. The mechanical effect caused by posterior enclavation prevents angle closure over the full 360 degrees of the iris.

The CBD measurements were not significantly different between the 2 groups. For posterior enclavation, the increase in ACD and in the distance to the cornea did not depend on the distance to the ciliary body (the antero-posterior translation of the IOL and the iridal plane having little effect on the periphery). Thus, unlike iris-sutured IOLs, an Artisan or Verisyse IOL that remains far from the ciliary body does not lead to chronic inflammation caused by irritation.^{37,38} The mean iris thickness was similar in the 2 populations, confirming that the quality of the iridal plane is preserved with both techniques.

Ultrasound biomicroscopy studies of modifications to the ICA have been reported²⁷⁻³⁰ (Table 2). Pereira and Cronemberger³⁰ studied the biometric changes in the ICA before and after cataract surgery in 21 patients (mean age 65 ± 10 years) with IOL implantation in the capsular bag. After phacoemulsification, UBM shows a mean increase in ACD of 850 μ m and a mean widening of the ICA of approximately 10 degrees. We observed an average widening of 21 degrees, an increase in mean ACD of 103 μ m, and an enlargement in the mean AOD of 198 μ m in Group B over Group A. In our study, both the ICA and AOD values were larger than those seen after cataract surgery. The widest angle measurements in Group A

Table 2. Comparison of the variations in AOD500 and ICA in previous studies and our study.

Parameter	Pavlin ²⁷⁻²⁹		Pereira and Cronemberger ³⁰		Present Study	
	Normal	Iris Plateau	Cataract Patients	Posterior Chamber IOL	Group B	Group A
Mean ACD (mm)	3.128 ± 0.37	2.228 ± 0.275	2.857 ± 0.402	3.732 ± 0.303	2.88 ± 0.77	1.857 ± 0.439
Mean AOD500 (mm)	0.347 ± 0.18	0.087 ± 0.839	0.303 ± 0.13	0.467 ± 0.6	0.489 ± 0.117	0.291 ± 0.22
Mean ICA (degrees)	30 ± 11	NC	25.05 ± 9.98	34.4 ± 9.9	49.847 ± 11.7	28.891 ± 18.47

Means \pm SD

ACD = anterior chamber depth; AOD500 = angle opening distance 500 μ m from the scleral spur; ICA = iridocorneal angle

were almost as high as those observed in patients with cataract, whereas those in Group B were higher than in all studied populations, even than in patients with posterior chamber IOLs.

Using Scheimpflug photography, Hayashi et al.³⁹ found a correlation between the increase in the ICA and ACD and a decrease in IOP after cataract surgery. Cataract extraction has been shown to be beneficial in patients with narrow- or closed-angle glaucoma.^{40,41} Steuhl et al.⁴¹ suggest that widening the ICA and increasing the ACD could facilitate trabecular aqueous humor filtration through a simple mechanical effect.

CONCLUSION

Pseudophakic bullous keratopathy represents a therapeutic challenge involving a triple procedure: PKP, IOL explantation, and secondary IOL implantation. With UBM, the anterior segment can be assessed with a high degree of accuracy, and it is a gold standard examination for objective, reliable evaluation of the 2 surgical approaches. In our study, IOL fixation over the iris in the anterior chamber led to more major complications including iridal synechias, endothelium-IOL contact, and ICA closure. The endothelial cell loss 1 year after surgery when the iris-claw IOL was enclavated in the anterior chamber was comparable to data reported in patients with iris-fixated phakic IOLs and PKP. In patients with the IOL retropupillary enclavation, the endothelial cell loss was lower. Anterior fixation of the Verisyse IOL caused secondary displacement of the iris and the IOL toward the graft endothelial surface, which may lead to long-term endothelial loss. Retropupillary implantation of the Verisyse IOL in a reversed position involves posterior translation of the iridal plane and of the optical zone, shown in UBM by a significantly deeper ACD, larger CED, and AOD than with anterior enclavation. The literature reports that good endothelial tolerance is directly correlated with ACD, which reinforces the interest in the posterior technique over the traditional technique when associated with PKP.

REFERENCES

1. Yilmaz A, Başer Z, Yurdakul NS, Maden A. Posterior chamber lens implantation techniques in posterior capsular rupture. *Eur J Ophthalmol* 2004; 14:7–13
2. Alió JL, Mulet ME, Shalaby AMM. Artisan phakic iris claw intraocular lens for high primary and secondary hyperopia. *J Refract Surg* 2002; 18:697–707
3. Budo C, Hessloehl JC, Izak M, et al. Multicenter study of the Artisan phakic intraocular lens. *J Cataract Refract Surg* 2000; 26:1163–1171
4. Pavlin CJ, Sherar MD, Foster FS. Subsurface ultrasound microscopic imaging of the intact eye. *Ophthalmology* 1990; 97:244–250
5. Tsubota K. Ocular surface management in corneal transplantation, a review. *Jpn J Ophthalmol* 1999; 43:502–508
6. Pavlin CJ, Foster FS. *Ultrasound Biomicroscopy of the Eye*. New York, NY, Springer-Verlag, 1995; 214
7. Garcia-Feijó J, Jiménez Alfaro I, Cuiña-Sardiña R, et al. Ultrasound biomicroscopy examination of posterior chamber phakic intraocular lens position. *Ophthalmology* 2003; 110:163–172
8. Rijneveld WJ, Beekhuis WH, Hassman EF, et al. Iris claw lens: anterior and posterior iris surface fixation in the absence of capsular support during penetrating keratoplasty. *J Refract Corneal Surg* 1994; 10:14–19
9. Kanellopoulos AJ. Penetrating keratoplasty and Artisan iris-fixated intraocular lens implantation in the management of aphakic bullous keratopathy. *Cornea* 2004; 23:220–224
10. Mohr A, Hengerer F, Eckardt C. Retropupillare Fixation der Irisklauenlinse bei Aphakie; Einjahresergebnisse einer neuen Implantationstechnik. *Ophthalmologe* 2002; 99:580–583
11. Dick HB, Aliyeva S, Tehrani M. Change in pupil size after implantation of an iris-fixated toric phakic intraocular lens. *J Cataract Refract Surg* 2005; 31:302–307
12. Trnavec B, Cernak A, Vodrazkova E. [Pigmentary glaucoma after implantation of the iris claw intraocular lens] [Czechoslovakian]. *Cesk Slov Oftalmol* 2005; 61:66–69
13. van der Schaft TL, van Rij G, Renardel de Lavalette JG, Beekhuis WH. Results of penetrating keratoplasty for pseudophakic bullous keratopathy with the exchange of an intraocular lens. *Br J Ophthalmol* 1989; 73:704–708
14. Singhal S, Sridhar MS. Late spontaneous dislocation (disenclavation) of iris-claw intraocular lenses. *J Cataract Refract Surg* 2005; 31:1441–1443
15. Yoon H, Macaluso DC, Moshirfar M, Lundergan M. Traumatic dislocation of an Ophtec Artisan phakic intraocular lens. *J Refract Surg* 2002; 18:481–483
16. Drews RC. Intermittent touch syndrome. *Arch Ophthalmol* 1982; 100:1440–1441
17. Moshirfar M, Barsam CA, Parker JW. Implantation of an Artisan phakic intraocular lens for the correction of high myopia after penetrating keratoplasty. *J Cataract Refract Surg* 2004; 30:1578–1581
18. Tahzib NG, Cheng YYY, Nuijts RMMA. Three-year follow-up analysis of Artisan toric lens implantation for correction of postkeratoplasty ametropia in phakic and pseudophakic eyes. *Ophthalmology* 2006; 113:976–984
19. Güell JL, Velasco F, Malecaze F, et al. Secondary Artisan-Verisyse aphakic lens implantation. *J Cataract Refract Surg* 2005; 31:2266–2271
20. Pop M, Payette Y. Initial results of endothelial cell counts after Artisan lens for phakic eyes; an evaluation of the United States Food and Drug Administration Ophtec Study. *Ophthalmology* 2004; 111:309–317
21. Bartels MC, Santana NTY, Budo C, et al. Toric phakic intraocular lens for the correction of hyperopia and astigmatism. *J Cataract Refract Surg* 2006; 32:243–249
22. Menezo JL, Cisneros AL, Rodriguez-Salvador V. Endothelial study of iris-claw phakic lens: four year follow-up. *J Cataract Refract Surg* 1998; 24:1039–1049
23. Tehrani M, Dick HB. Iris-fixated toric phakic intraocular lens: three-year follow-up. *J Cataract Refract Surg* 2006; 32:1301–1306
24. Saxena R, Landesz M, Noordzij B, Luyten GPM. Three-year follow-up of the Artisan phakic intraocular lens for hypermetropia. *Ophthalmology* 2003; 110:1391–1395
25. Tehrani M, Dick HB. The “sandwich technique” for iris-fixated phakic intraocular lens implantation. *J Refract Surg* 2006; 22:96–98

26. Pop M, Payette Y, Mansour M. Ultrasound biomicroscopy of the Artisan phakic intraocular lens in hyperopic eyes. *J Cataract Refract Surg* 2002; 28:1799–1803
27. Pavlin CJ, Foster FS. Ultrasound biomicroscopy in glaucoma. *Acta Ophthalmol Suppl* 1992; 204:7–9
28. Pavlin CJ, Harasiewicz K, Foster FS. Ultrasound biomicroscopy of anterior segment structures in normal and glaucomatous eyes. *Am J Ophthalmol* 1992; 113:381–389
29. Pavlin CJ, Ritch R, Foster FS. Ultrasound biomicroscopy in plateau iris syndrome. *Am J Ophthalmol* 1992; 113:390–395
30. Pereira FAS, Cronemberger S. Ultrasound biomicroscopic study of anterior segment changes after phacoemulsification and foldable intraocular lens implantation. *Ophthalmology* 2003; 110:1799–1806
31. Rutnin SS, Pavlin CJ, Slomovic AR, et al. Preoperative ultrasound biomicroscopy to assess ease of haptic removal before penetrating keratoplasty combined with lens exchange. *J Cataract Refract Surg* 1997; 23:239–243
32. Yang H, Lin Z, Chen X, Wang N. [Intraobserver reproducibility study of parameters for measurement of position and height of ciliary process by ultrasound biomicroscopy] [Chinese]. *Yen Ko Hsueh Pao* 1999; 15:103–106
33. de Souza Filho EC, de A, Marigo F, Oliveira C, et al. Reprodutibilidade intra-observador de medidas morfométricas do segmento anterior em olhos normais pela biomicroscopia ultra-sônica (UMB). *Arq Bras Oftalmol* 2005; 68:177–183
34. Spaeth GL, Azuara-Blanco A, Araujo SV, Augsburgger JJ. Intra-observer and interobserver agreement in evaluating the anterior chamber angle configuration by ultrasound biomicroscopy. *J Glaucoma* 1997; 6:13–17
35. Wong SK, Stark WJ, Gottsch JD, et al. Use of posterior chamber lenses in pseudophakic bullous keratopathy. *Arch Ophthalmol* 1987; 105:856–858
36. Waring GO III. Management of pseudophakic corneal edema with reconstruction of the anterior ocular segment. *Arch Ophthalmol* 1987; 105:709–715
37. Piette S, Canlas OAO, Tran HV, et al. Ultrasound biomicroscopy in uveitis-glaucoma-hyphema syndrome. *Am J Ophthalmol* 2002; 133:839–841
38. Apple DJ, Mamalis N, Lofffield K, et al. Complications of intraocular lenses. A historical and histopathological review. *Surv Ophthalmol* 1984; 29:1–54
39. Hayashi K, Hayashi H, Nakao F, Hayashi F. Changes in anterior chamber angle width and depth after intraocular lens implantation in eyes with glaucoma. *Ophthalmology* 2000; 107:698–703
40. Gunning FP, Greve EL. Lens extraction for uncontrolled angle-closure glaucoma: long-term follow-up. *J Cataract Refract Surg* 1998; 24:1347–1356
41. Steuhl KP, Marahrens P, Frohn C, Frohn A. Intraocular pressure and anterior chamber depth before and after extracapsular cataract extraction with posterior chamber lens implantation. *Ophthalmic Surg* 1992; 23:233–237



First author:

Jean-Jacques Gicquel, MD, MS